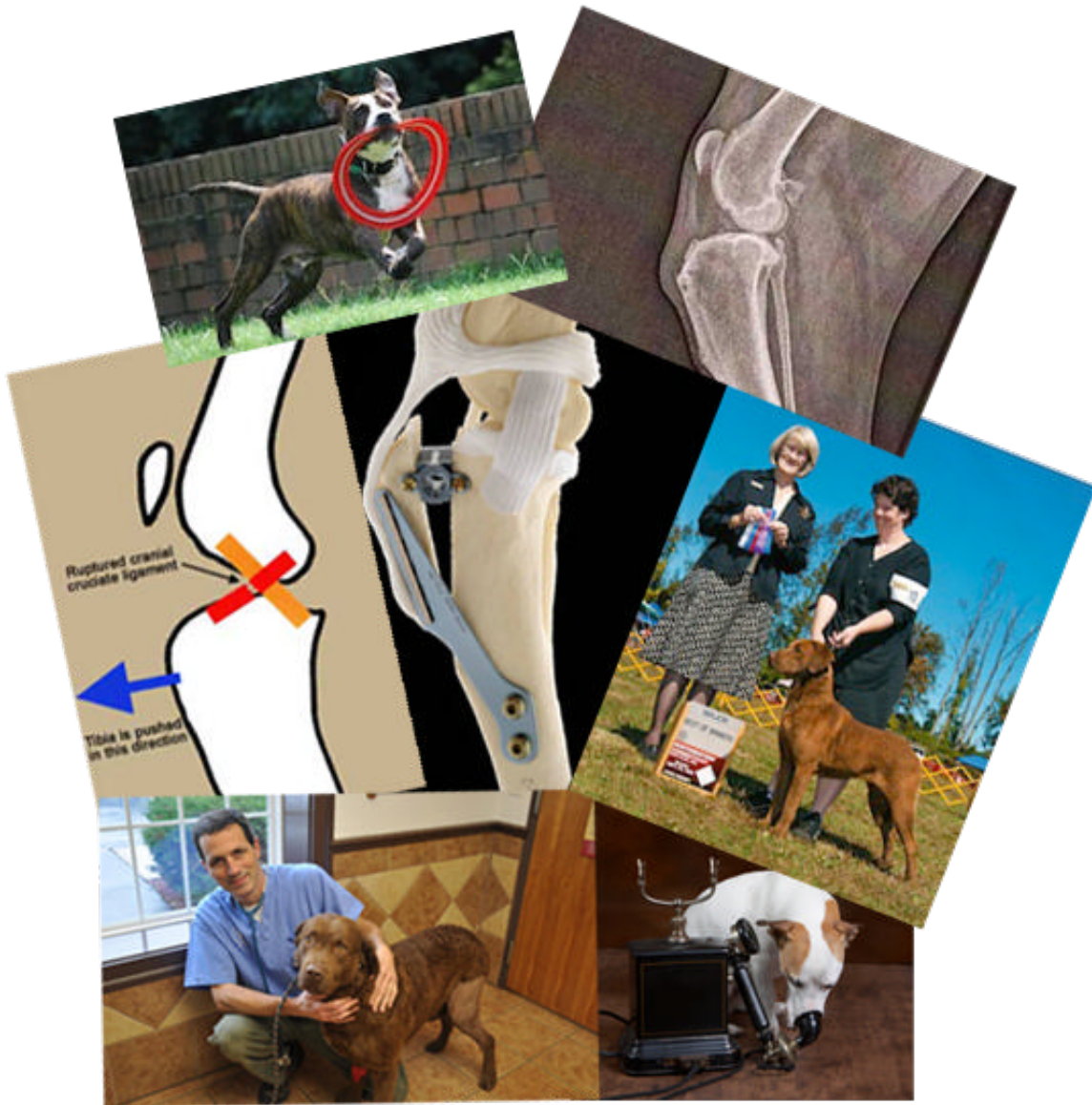

Canine Knee Surgery

Solutions for Your Dog's Knee Injury



by Dr. David Leahy

Solutions for Your Dog's Knee Injury

<i>Anterior Cruciate Ligament Injury</i>	1
<i>We need define our terms so we can understand the problem better</i>	2
<i>Let's now explain the function of the stifle joint</i>	3
<i>So what happens when the CCL ruptures?</i>	4
<i>Let's talk solutions. Here is where the options start:</i>	7
<i>The stifle joint is like a hinge joint , but there is a bit more to it.</i>	9
<i>... Newer procedures that modify the stifle joint geometry.</i>	9
<i>Tibial Plateau Leveling Osteotomy (or TPLO)</i>	10
<i>Tibial Tuberosity Advancement (or TTA)</i>	11
<i>X-ray</i>	12
<i>"...What is the best procedure to do for a CCL rupture?"</i>	13
<i>I prefer the TTA method for several reasons.</i>	13

Anterior Cruciate Ligament Injury

If your dog has been diagnosed with a torn ACL (anterior cruciate ligament) then most likely your veterinarian has suggested some form of surgical correction for this problem. Your vet has probably told you that you have surgical options and may have referred you to an orthopedic specialist to have surgery performed.

Unfortunately, we veterinarians sometimes speak in ways that leave you confused, making it difficult for you to make appropriate decisions for your pet. I would like to try to explain to you, in plain English, what is involved in an ACL (anterior cruciate ligament) injury and its repair.

We need define our terms so we can understand the problem better

In canine patients, the ACL is properly called a CCL, or cranial cruciate ligament. The term ACL refers to the same structure, but in humans. Your veterinarian may refer to it as an ACL because most people have heard of athletes with torn ACL's and understand what part of the anatomy we are speaking of. From here on out, I'll be using the proper term, cranial cruciate ligament, CCL.

The knee joint (the joint where the CCL resides) is properly called the stifle joint. The stifle joint is composed of three major bones; the femur, the tibia, and the patella. Those three, in humans, are your thighbone (femur), shin bone (tibia) and knee cap (patella). The ends of these bones are surrounded by cartilage, the slippery stuff that allows for movement. They sit together in a fluid called joint fluid, and there is a seal around the joint called a joint capsule.

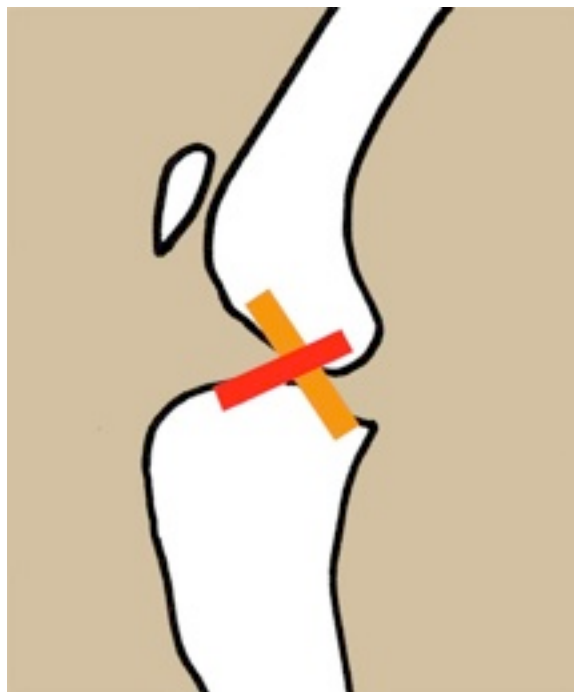Inside the joint sits the CCL (cranial cruciate ligament) and another ligament called the caudal cruciate ligament. They form a cross shape, hence the name cruciate (meaning cross). This is important later when explaining joint function.

Also in the joint are two shock absorbers called meniscus. When you see an X-Ray of a stifle joint, the femur and tibia appear to be separated by space, but they are not. The femur sits on top of the meniscus. The meniscus is not visible on an X-Ray. For that matter, ligaments are not visible on an X-Ray either- so you cannot see the CCL on an X-Ray.

Let's now explain the function of the stifle joint

The stifle joint is a complex joint; but I will simplify it so that its function can be understood. First, compare the stifle to a hinge that can only swing two ways, forward and backward. The center of the hinge is inside of the stifle joint. The forward swing is called extension, and occurs during weight bearing. The backward swing is called flexion and occurs during the non-weight bearing, or swing, phase of gait motion.

As everyone knows, when you walk, only one foot is on the ground at any one time. Now most importantly, to keep the femur (thighbone) in alignment with the tibia (shin) during motion are the cranial and caudal cruciate ligaments. These two ligaments, in the shape of an X, or cross, maintain appropriate contact between the two bones. The illustration shows the location of both ligaments.

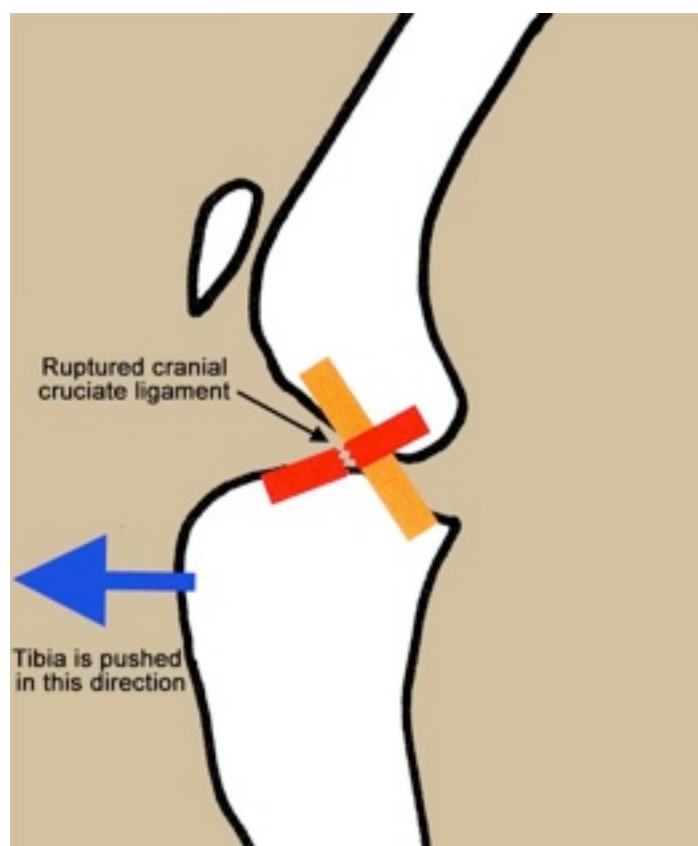


The CCL attaches in the back of the femur and comes forward to attach to the front of the tibia. The caudal cruciate ligament attaches on the front of the femur, and goes backwards to attach to the back of the tibia. Where they cross each other is the “hinge” point.

So what happens when the CCL ruptures?

Well, we have all had a door break a hinge, and then the door won't open or close very well- usually causing a lot of scraping on the floor. The same thing happens in the stifle joint. The bones are no longer in proper alignment, and the joint doesn't work well, causing pain, inflammation, and cartilage damage.

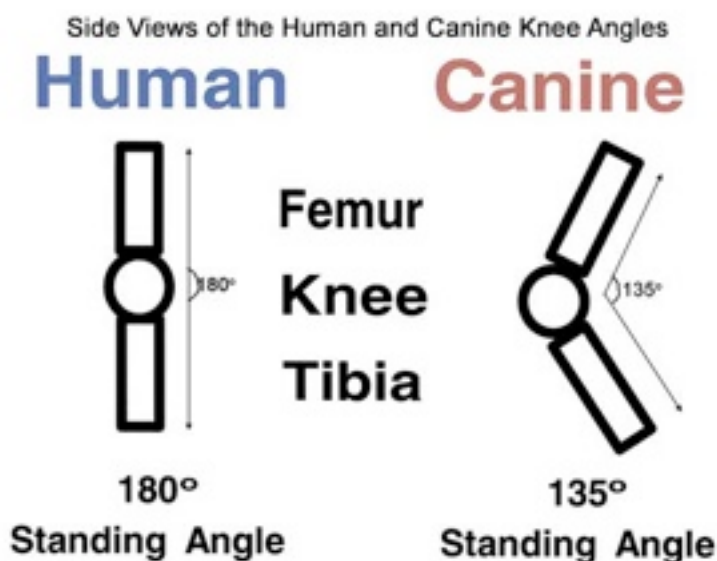
Typically, when the CCL ruptures, the femur rides backwards on the tibia, and the tibia wants to come forward. The fancy term for this phenomenon is cranial tibial subluxation. The bottom line is that it hurts!



Most clients bringing in a pet with a CCL rupture say that it occurred during running, fetching, or playing with another dog. To the owner, it may appear as an acute (or quick onset) injury, but that is not so. This is a chronic disease in dogs, unlike humans. Human ACL injuries are almost always the result of athletic trauma.

You may ask, “*Why the difference between human and canine knee ligament injuries?*”

First, the stance of the canine knee is different than the stance of the human knee. People stand straight up, with their femur directly on top of their tibia, having a joint angle of 180°. Dogs stand with an angle of 135°



As you can see, every time that a dog stands, the bone alignment is dependent upon an intact CCL to hold the bones in place in the stifle (knee) joint. Chronic wear and tear on the CCL causes it to ultimately fail.

The best analogy is a rope; the CCL is like a rope made up of many fibers. With time and stress, the fibers of the rope slowly break down until it is so weak that it can't do its job anymore and breaks.

Most dogs come see me when the CCL finally breaks and the dog is so lame that it either can't bear any weight, or can only touch its toes to the ground.

You can certainly have a partial tear which is just as painful, and leaves the CCL just as incompetent. This is important because CCL injury is always accompanied by some form of degenerative joint disease or osteoarthritis. This arthritis is not reversible.

Most surgeries slow the progression of arthritis, but do not reverse what is already there; therefore the stifle is never the same as if it had an intact CCL. (The world is not perfect!)

Let's talk solutions. Here is where the options start:

The names of each surgery can be confusing, and all of them have different theories as well. The two broad categories are surgeries that:

1. attempt replacement of the broken CCL, and
2. surgeries that change the geometry of the stifle so that the CCL is not needed.

The surgeries that replace the broken ligament are further divided into two major categories, namely:

- intracapsular repair and
- extracapsular repair.

The capsule refers to the joint capsule, or seal, that surrounds the stifle joint.

The intra-capsular repair uses the body's natural material to recreate the CCL. This procedure is commonly done in human medicine, but has fallen to the wayside in veterinary medicine, as the results have not been as good as in other procedures. I won't perform an intracapsular repair, but stay tuned, some researchers are looking at synthetic material inside the joint, and this surgery may make a comeback.

The extracapsular repair is a common form of CCL repair. There are many different ways and materials available to stabilize the stifle joint. This is where much confusion occurs, as all of these procedures have different names, but the theory is the same: re-create the CCL, outside of the joint.

Of these procedures, the only one to use the body's natural material is a procedure called the lateral fibular head transposition- a fancy name for re-creating the CCL with the lateral collateral ligament. All of the other forms of extracapsular repair use synthetic materials- either polyester, nylon, or proprietary materials (meaning that it is a patented material).

All of these procedures have two things in common:

- they attach on the side of the femur, and
- come forward to attach to the front side of the tibia.

Terms you may hear your vet use are

- lateral suture stability,
- modified Flo,
- femoral tibial suture,
- Tight Rope™ ,
- Bone Biters™,

and many others.

Some drill tunnels, some use anchors, and some pass around another bone. They are all on the outside of the stifle joint. These procedures are commonly done on smaller dogs, and can be quite successful. They do have their share of problems, especially with larger dogs.

Big dogs can break their real CCL ligament, and they can certainly break or stretch the fake one! As this artificial material is placed on the outside surface of the joint, normal joint mechanics are inhibited.

The stifle joint is like a hinge joint , but there is a bit more to it.

During the stance phase (or weight bearing), the tibia bone does rotate internally a small amount in a normal dog, but this internal rotation is inhibited by the artificial material placed outside of the joint. (I told you vets want to call the stifle joint complex!)

The procedures that we talked about above can still can lead to a non-lame dog, and may be recommended for smaller dogs or older non-active dogs; however, their shortcomings have led to...

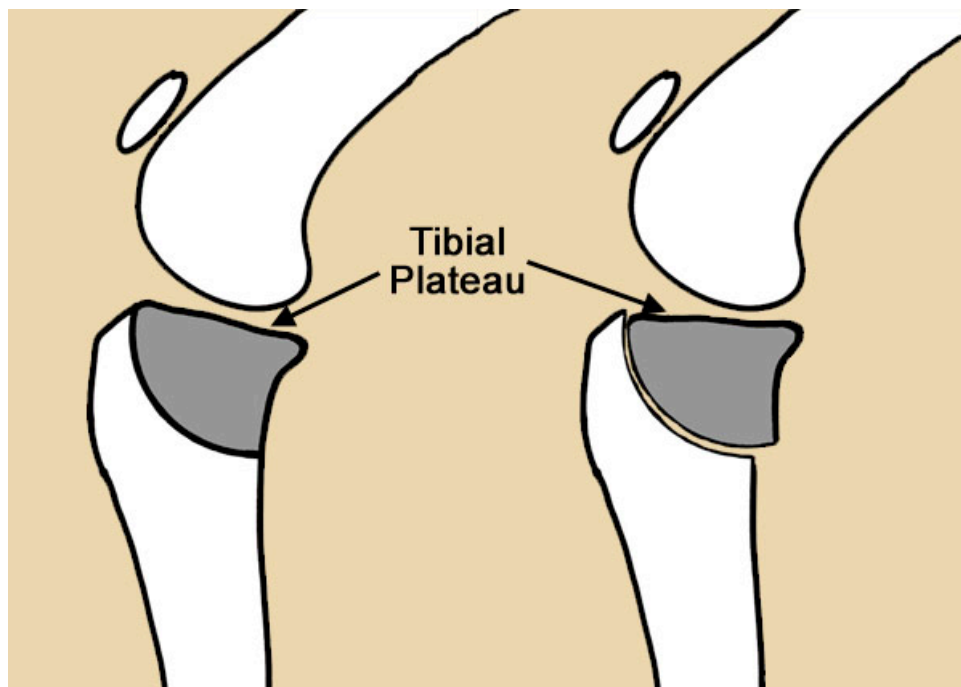
... Newer procedures that modify the stifle joint geometry.

Geometry is the study of angles and forces, and these newer procedures use that study to modify joint function by changing angles inside the stifle joint, so that the CCL is not necessary.

These procedures differ greatly from the previous ones that attempt to re-create the CCL. The two most common procedures are the TPLO (tibial plateau leveling Osteotomy), and the TTA, (tibial tuberosity advancement). Both accomplish the same thing, by cutting the tibia bone, making a bony shift, and using a bone plate to hold the cut piece of bone in place.

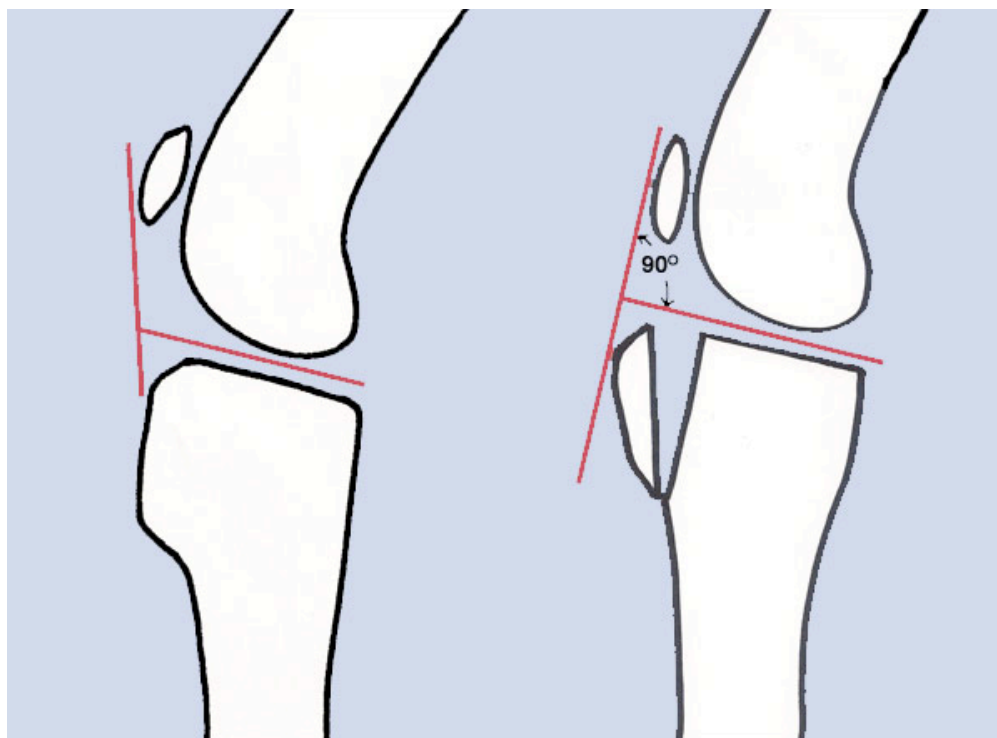
Tibial Plateau Leveling Osteotomy (or TPLO)

The TPLO, first developed in the mid 1990's, is explanatory by dissecting the name. The *tibia* is the bone involved: tibial = bottom bone of the stifle joint. *Plateau* is the name for the top of the tibia bone inside the joint, where the femur sits. *Leveling* is in relation to the floor, giving the femur a level spot to sit on the tibial plateau. *Osteotomy* is a fancy term meaning to cut bone. (The actual angles measured and cut are not to the floor of the surgery room, but this simplifies a basic understanding) *See illustration.*



Tibial Tuberosity Advancement (or TTA)

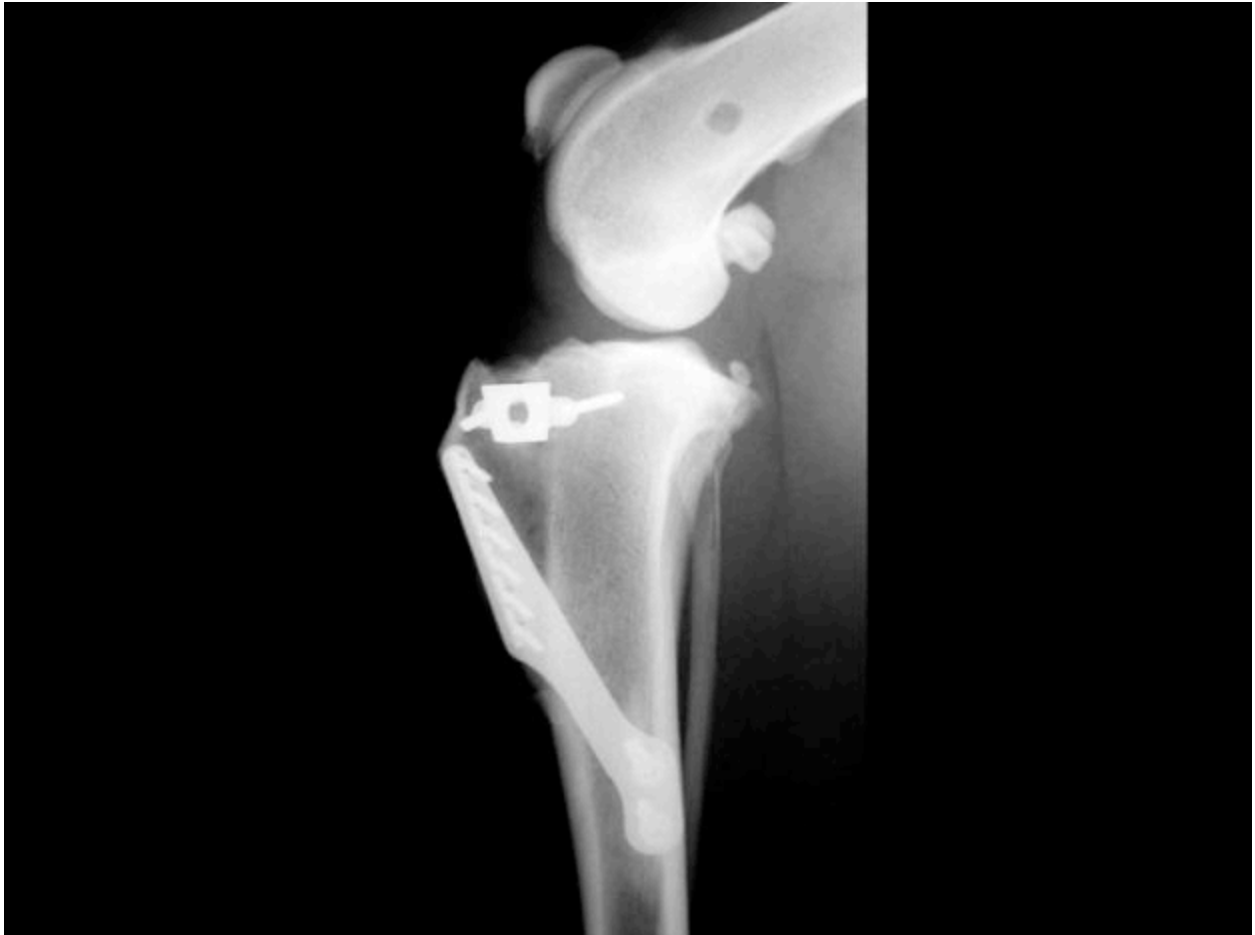The TTA, or tibial tuberosity advancement, is explanatory also by its name. *Tibial* = relating to the tibia, the lower half of the of the stifle joint. The tuberosity is the front edge of the tibia just below the stifle joint where the patellar tendon attaches, and *advancement*, meaning to bring forward. The tibial *tuberosity* (patellar tendon attachment) is just moved forward a certain amount and a spacer is screwed in place to hold it together until the bone cut is healed. The amount of advancement is determined by a right angle (90°) of the patellar tendon to the tibial plateau. See illustration.



By advancing the tibial tuberosity to a 90° angle, the stifle joint is stabilized by shifting the weight to the caudal cruciate ligament. In effect there is no longer a need for the cranial cruciate ligament.

If you wish to read in further detail on the mechanics of the TTA procedure, visit the inventor's website: www.kyonpharma.com - on that website is an exhaustive description of the forces in play on stifle mechanics and how the TTA works. The diagrams are very well done but can be confusing due to the complexity of the stifle joint!

X-ray



This is an X-ray of the tibial tuberosity advancement surgery.

I often get asked...

“...What is the best procedure to do for a CCL rupture?”

That question can only be answered on an individual basis, as each patient is a unique situation and many factors of the patient's anatomy and lifestyle come into play when making a decision. For most of my patients that are big and active, I do recommend a TTA. If a patient is older, but still very active, I will still recommend a TTA. Some veterinarians will recommend a TPLO and that is fine, as neither are superior in regards to outcome -both procedures are highly successful.

As of this date in 2010, there are no known veterinary surgeons in the world that have learned the TTA method and then switched to using the TPLO method. However, there are plenty of veterinary surgeons that began with the TPLO method and have since started using the TTA instead.

I prefer the TTA method for several reasons.

- The procedure itself is easier to perform, and highly reproducible, meaning we get consistently good results. I want all of my patients that have a TTA surgery to do well!
-
- TTA patients begin using the leg more quickly than patients having a TPLO procedure, because with the TTA procedure, the tibia is cut only in a non-weight bearing area: The femur sits on top of the uncut portion of the tibia, not through a line cut across the shaft of the tibia, as in the TPLO procedure.
-
- This means that the chances of a catastrophic mistake or post-surgical injury are much less with the TTA.